

# Surgical Correction of Metopic Craniosynostosis: A 3-D Photogrammetric Analysis of Cranial Vault Outcomes

The Cleft Palate-Craniofacial Journal  
2019, Vol. 56(2) 231-235  
© 2018, American Cleft Palate-  
Craniofacial Association  
Article reuse guidelines:  
sagepub.com/journals-permissions  
DOI: 10.1177/1055665618775729  
journals.sagepub.com/home/cpc



Olivia E. Linden, MD<sup>1</sup>, Vanessa M. Baratta, MD<sup>2</sup>, Jose A. Gonzalez, BS<sup>3</sup>,  
Margaret E. Byrne, RN<sup>4</sup>, Petra M. Klinge, MD, PhD<sup>5</sup>, Stephen R. Sullivan, MD, MPH<sup>6</sup>,  
and Helena O. Taylor, MD, PhD<sup>6</sup>

## Abstract

**Objective:** To evaluate 3-dimensional (3-D) photogrammetry as a tool for assessing the postoperative head shape of patients who had undergone cranial vault remodeling for metopic synostosis.

**Design:** We prospectively analyzed images of patients with metopic craniosynostosis who had undergone anterior cranial vault remodeling and age-matched controls. To ensure standardized facial orientation, each 3-D image was positioned to “best fit” the preoperative face by aligning 6 soft tissue landmarks. Forehead measurements were taken from a standardized position behind the surface of the face to landmarks placed in a ray configuration across the forehead.

**Setting:** Academic teaching hospital.

**Patients, Participants:** Thirteen pediatric patients with metopic craniosynostosis who had undergone anterior cranial vault remodeling and age-matched controls.

**Interventions:** Images were taken preoperatively, immediately postoperatively, and over 1-year postoperatively.

**Main Outcome Measures:** Forehead contours preoperatively and postoperatively, with statistics performed using a multivariate analysis of variance shape analysis.

**Results:** Mean postoperative follow-up was 1.8 (0.6) years. The average distance from the origin to forehead landmarks was 55.1 (3.4) mm preoperatively, 59.3 (0.7) mm immediate postoperatively, 59.1 (1.0) mm 1-year postoperatively, and 59.4 (0.6) mm in controls. Postoperative metopic forehead contours varied significantly from preoperative contours ( $P < .01$ ), while there was no statistical difference between the 2 postoperative time points ( $P = .70$ ). One-year postoperative patients were not significantly different from their age-matched controls ( $P > .99$ ).

**Conclusions:** Preoperative metopic forehead contours varied significantly from postoperative contours. Cranial reconstructions approximated the foreheads of normal controls, and reconstructions were stable at more than 1-year follow-up.

## Keywords

3-D photogrammetry, metopic craniosynostosis

## Introduction

Craniosynostosis, the premature fusion of cranial sutures, occurs in approximately 1 of every 2000 live births (Cohen and MacLean, 2000). Corrective surgery, that is, cranial vault expansion, aims to separate the fused cranial bones, restore head shape, and allow for normal cranial development. In the past, quantitative measurements of surgical outcomes have relied on 2-dimensional anthropometric measurements or computed tomography (CT). While anthropometric measurements can be technically difficult and time consuming in a young

<sup>1</sup> Department of Medicine, Harvard Medical School, Cambridge Health Alliance, Cambridge, MA, USA

<sup>2</sup> Department of General Surgery, Yale Medical School, Yale New Haven Hospital, New Haven, CT, USA

<sup>3</sup> Warren Alpert Medical School of Brown University, Providence, RI, USA

<sup>4</sup> Division of Plastic and Reconstructive Surgery, Rhode Island Hospital and Hasbro Children's Hospital, Providence, RI, USA

<sup>5</sup> Department of Neurosurgery, Warren Alpert Medical School of Brown University, Rhode Island Hospital and Hasbro Children's Hospital, Providence, RI, USA

<sup>6</sup> Division of Plastic and Reconstructive Surgery, Mount Auburn Hospital, Cambridge, MA, USA

## Corresponding Author:

Helena O. Taylor, Division of Plastic and Reconstructive Surgery, Mount Auburn Hospital, 300 Mount Auburn Street, Suite 304 Cambridge, MA 02138, USA.

Email: htaylor@mah.harvard.edu

patient population, CT outcome analyses are limited in that they primarily provide information on bony cranial structures and carry the downside of radiation. In the literature, there have been few attempts to assess the facial soft tissues with CT (Steinbacher et al., 2011).

In recent years, 3-dimensional (3-D) photogrammetry has had an increasing presence in quantitatively evaluating plastic surgery outcomes. While standard anthropometric measurements were confined to linear distances, angles, and area calculations of the body's surface, 3-D photogrammetry enables the analysis of soft tissue topography and volumes (Honrado and Larrabee, 2004; Chan et al., 2013). Several studies have indicated other benefits to 3-D imaging including high precision, accuracy, and reproducibility (Kau et al., 2007; Wong et al., 2008; Plooij et al., 2009; Lübbers et al., 2010; Othman et al., 2013).

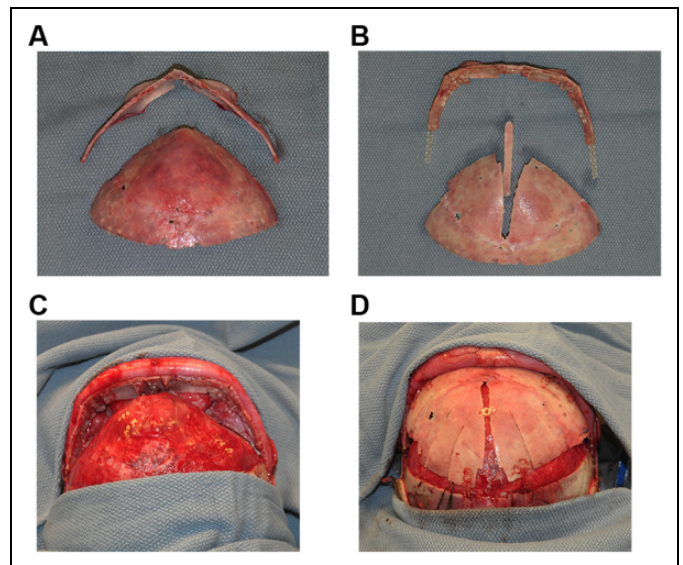
The fast, noninvasive nature of 3-D photogrammetry eliminates the concern of pediatric sedation and is free of the radiation concerns associated with CT imaging. Since CT imaging is seldom indicated for postsurgical evaluation, 3-D images enable the collection of postoperative images (Plooij et al., 2009). This creates the opportunity for pre- and postoperative quantitative comparisons at desired time intervals.

Pediatric craniofacial surgeons share a need to objectively assess morphological improvement in craniosynostosis patients following surgical correction (Hankinson et al., 2010; Wilbrand et al., 2012; Wong et al., 2013; Wes et al., 2014). Recent studies using 3-D photogrammetry for metopic synostosis have focused primarily on evaluating volumetric changes, such as frontal and total intracranial volumes, head circumference, and anterior to posterior ratios; however, these are less specific in characterizing the change in head shape morphology (Wilbrand et al., 2012; Seruya et al., 2014; Weathers et al., 2014; Freudl-sperger et al., 2015). With this in mind, we aimed to elucidate additional means for quantitatively evaluating the postoperative morphologic changes in patients with surgical correction for metopic craniosynostosis using 3-D photogrammetry.

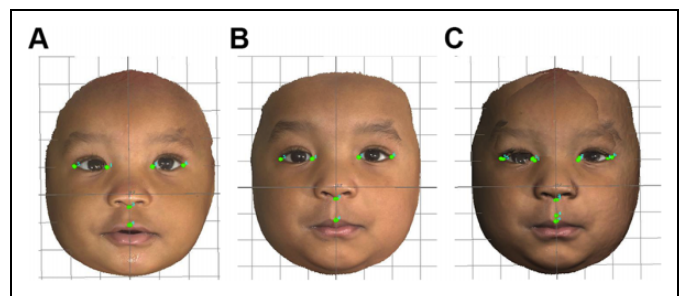
## Methods

Following internal review board approval, we identified pediatric patients with CT-diagnosed metopic synostosis, both syndromic and nonsyndromic, at a single academic institution from 2011 to 2014. We excluded patients who had involvement of multiple sutures or patients without preoperative imaging.

Every patient was seen in a multidisciplinary clinic and had preoperative photogrammetric imaging using the Canfield Vectra stereophotogrammetry system (Canfield Imaging Systems, Fairfield, New Jersey). Demographic data including age, gender, and race were obtained. All anterior cranial vault expansion procedures were performed in conjunction with neurosurgery and plastic surgery and included reshaping of the fronto-orbital bandeau. The surgical technique is shown sequentially in Figure 1 demonstrating the (A) removal, (B) reshaping, (C) advancement of the bandeau, and (D) the reconstruction of the forehead. Of note, the craniectomy was



**Figure 1.** Photographic illustration of anterior cranial vault expansion procedure. The surgical technique is shown sequentially in these images, showing the (A) removal, (B) reshaping, (C) advancement of the bandeau, and (D) the reconstruction of the forehead.

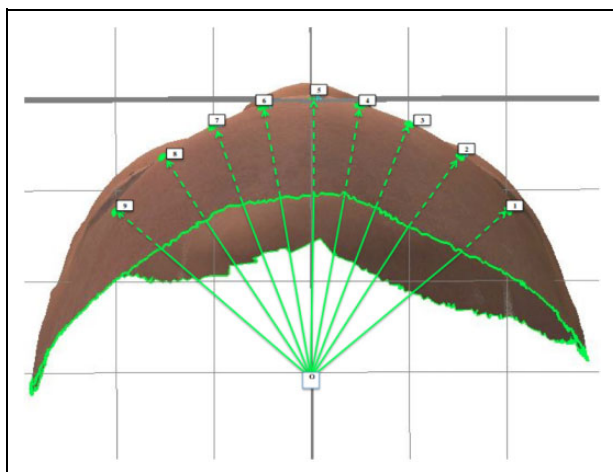


**Figure 2.** Six soft tissue landmarks (medial and lateral canthi, subnasale, procheilion) were used to optimally align the facial scans in 3-dimensional space. A, Preoperative image. B, Postoperative image. C, Overlapped "best fit" image.

extended posterior to the coronal suture, and the bandeau was designed from the zygomaticofrontal suture to 1 cm above the supraorbital rim. Following surgery, most patients underwent immediate (defined as within the first 6 months) and greater than 1-year follow-up imaging again using the Canfield Vectra imaging system.

To ensure standardized facial orientation, each 3-D image was positioned using a Procrustes technique to "best fit" the preoperative facial image by aligning 6 soft tissue landmarks: the medial and lateral canthi, subnasale, and procheilion (Cupid bow; Figure 2). These landmarks were chosen based on previous studies that have demonstrated high levels of reproducibility with landmark placement on the midface and have shown a lesser degree of positional change with cranial vault manipulation and physiological growth over time (Plooij et al., 2009; Wilbrand et al., 2012; Othman et al., 2013).

Analysis was performed in 3 ways. First, we assessed the absolute average distance from the origin to the soft tissue



**Figure 3.** Superior view of modified vector analysis, demonstrating landmark placements on the forehead of a patient with metopic craniosynostosis in reference to the origin (O).

landmarks. Second, we used a multivariate analysis of variance (MANOVA) shape analysis to directly compare individual forehead shapes. Lastly, we utilized a 3-D qualitative analysis with color maps.

We modified a vector analysis technique originally utilized by Marcus et al. (2006) for analysis of sagittal synostosis with CT scans. In this earlier study, the dorsum of the sella turcica was used as an origin to measure distances to the outer table of the cranium in a midsagittal view (Marcus et al., 2006). We refitted this method to utilize soft tissue landmarks in an axial view to highlight the morphological changes seen in metopic synostosis. All distances were measured from an origin positioned in a horizontal plane 60 mm behind the surface of the face and 20 mm above the glabella. Distances were then measured from this origin to 9 soft tissue landmarks spaced every 10 mm across the soft tissues of the forehead (Figure 3).

For comparison, we imaged age-matched controls with no history of craniofacial disorders, facial surgery, or facial trauma. Each over 1-year postoperative patient image was compared to age-matched controls within  $\pm 0.2$  years of age.

Color mapping was applied to qualitatively compare the changes between the preoperative and longest follow-up images within the Canfield Vectra system. With the images “best fit” in 3-D orientation using the Procrustes technique described above, we isolated the upper third of the face, defined from the hairline to glabella, and applied color maps based on the distances between the 2 surfaces to visualize areas of relative elevation and depression.

### Statistical Analysis

Statistical analysis included a MANOVA performed using IBM, Armonk, NY, SPSS Statistics. A MANOVA shape analysis takes into account that individual points along a curve are dependent on preceding and succeeding points. This allowed the 9 dependent variables (individual forehead landmarks) to

Patient Data	Subjects	Controls
Sex (Male : Female)	10 : 3	5 : 3
Age at Preop (years), n = 13		
Median $\pm$ SD	0.9 $\pm$ 0.8	
(Range)	(0.3 - 3.4)	
Age at Immediate Postop (years), n = 11		
Median $\pm$ SD	1.6 $\pm$ 1.1	
(Range)	(0.7 - 3.8)	
Age at >1 yr Postop (years), n = 8		
Median $\pm$ SD	3.0 $\pm$ 1.0	3.0 $\pm$ 1.1
(Range)	(1.8 - 5.1)	(1.8 - 5.2)

**Figure 4.** Patient characteristics.

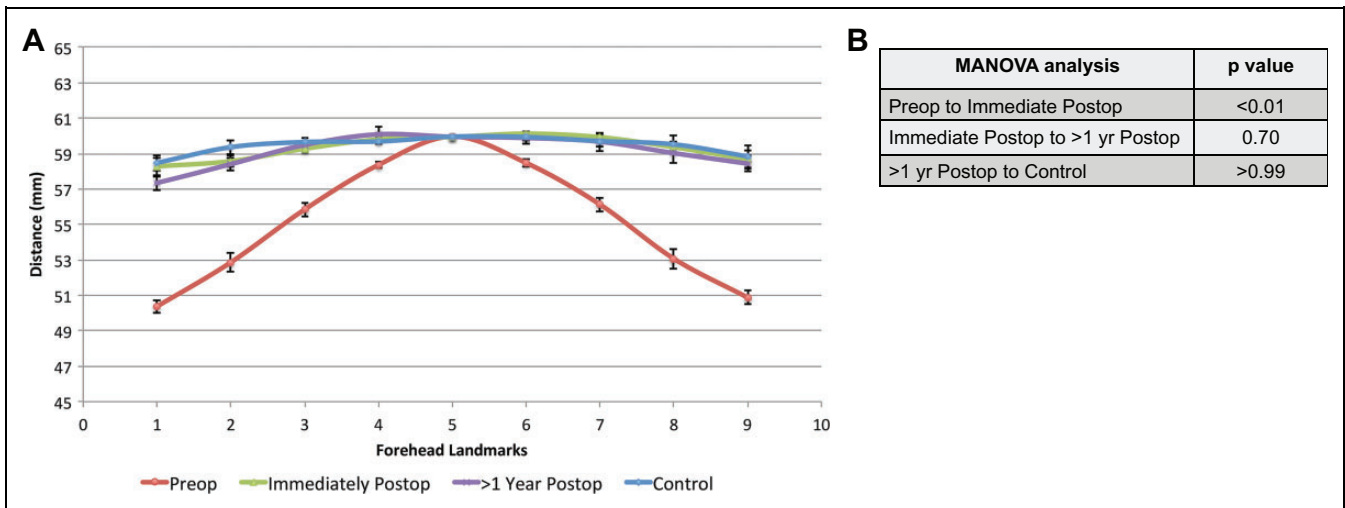
undergo canonical compression into a single dependent super-variable, the Pillai’s trace statistic, allowing direct comparison between shapes, and thus yielding a *P* value. Values of *P* less than .05 were considered significant.

### Results

In total, we analyzed images of 13 pediatric patients with CT-diagnosed metopic craniosynostosis that met the inclusion criteria (Figure 4). The mean patients’ age at preoperative imaging (n = 13) was  $0.9 \pm 0.8$  years (range 0.3-3.4 years). At immediate postoperative imaging, the mean patients’ age (n = 11) was  $1.6 \pm 1.1$  years (range 0.7-3.8 years). The average time between cranial vault expansion to immediate postoperative imaging was  $0.2 \pm 0.1$  years (range 0.1-0.5 years) and varied individually with patients depending on factors such as patient follow-up, scheduling, and availability of imaging.

At greater than 1-year postoperative imaging, the mean patient’s age (n = 8) was  $3.0 \pm 1.0$  years (range 1.8-5.1 years). The average time between cranial vault expansion and greater than 1-year postoperative imaging was  $1.8 \pm 0.6$  years (range 1.0-2.8 years). Age-matched controls (n = 8) had a mean age of  $3.0 \pm 1.1$  years (range 1.8-5.2) and were all within  $\pm 0.2$  years of 1-year postoperative patient ages, with a mean difference in age of  $0.1 \pm 0.1$  years (range 0.0-0.2 years).

Our results are graphically summarized in Figure 5. Our first analysis looked at the average absolute distance from the origin to the soft tissue of the forehead. The average distance in preoperative faces was  $55.1 \pm 3.4$  mm, compared to  $59.3 \pm 0.7$  mm,  $59.1 \pm 1.0$  mm, and  $59.4 \pm 0.6$  mm for the immediate postoperative, over 1-year postoperative, and age-matched control images, respectively. Secondly, using a MANOVA shape analysis to compare the contours, we found a significant difference between the preoperative and the immediate postoperative curvatures (*P* < .01). There was no significant difference between the 2 postoperative forehead contours (*P* = .70). The age-matched control contour clustered tightly with both postoperative tracings, and overall, there was no difference



**Figure 5.** Graphical representation of the averaged data for the soft tissue forehead contours with standard error bars. The individual forehead landmarks are represented on the x-axis, and the y-axis is the distance from the origin to the forehead surface, in mm. The red line traces the preoperative shape and demonstrates the limited projection of the lateral orbital rims and prominent projection at the midline. The green line represents the immediate postoperative forehead, while the purple line is greater than 1-year follow-up. There was a significant difference between the preoperative (red) and the immediate postoperative (green) shapes ( $P < .01$ ), and no difference between the 2 postoperative (green, purple) curves ( $P = .70$ ). The age-matched controls (blue) cluster tightly with both postoperative tracings. Overall, there was no difference between the controls and the over 1-year postoperative curves ( $P > .99$ ).

between the normal controls and the over 1-year postoperative curves ( $P > .99$ ).

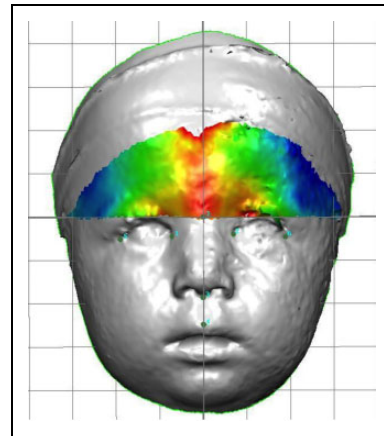
When comparing 1-year postoperative images to their individual preoperative scans ( $n = 8$ ), an average of  $3.9 \pm 2.6$  mm was gained across the forehead, with an average positive distance of  $7.3 \pm 1.1$  mm (range 5.3-10.0 mm) at the most lateral landmarks.

Lastly, color mapping of the upper facial third further elucidated the trend we saw in quantitative contouring, demonstrating the relative volume deficit at the midline and lateral expansion (Figure 6).

## Conclusions

Three-dimensional photogrammetry provides a safe and quantitative assessment of postsurgical changes and their stability. Through the use of 3-D photogrammetry, we were able to quantitatively document the morphology of postsurgical outcomes of metopic synostosis and compare these results to controls. Our study concluded that preoperative metopic forehead contours varied significantly from postoperative contours, while cranial reconstructions approximated the foreheads of normal controls. The reconstructions were stable at more than 1-year follow-up and did not show signs of significant recurrence at our average follow-up time of  $1.8 \pm 0.6$  years postoperatively. Following cranial vault expansion, our over 1-year postoperative patient group had a measurable  $3.9 \pm 2.6$  mm gain across the forehead, with the greatest amount of change laterally. On average, there was a positive distance addition of  $7.3 \pm 1.1$  mm at the most lateral landmarks.

Over the course of our study, we experienced a high attrition rate, with 13 patients imaged preoperatively, 11 imaged



**Figure 6.** Example of a color map overlaying a preoperative and over 1-year postoperative images “best fit” in 3-D orientation. Color mapping was used to highlight changes in the upper third of the face and further demonstrate the relative volume deficit at the midline, shown in red, and the lateral expansion in blue after surgical correction.

immediately postoperatively, and 8 imaged at over 1-year follow-up. Though our current clinical data still demonstrate statistical significance, in the future we will continue to monitor and collect images on our longer follow-up patients.

Other limitations of our study include the sample size and duration of follow-up, as outcomes can vary and show recurrence in 5 to 10 years postoperatively. Longer term studies have demonstrated a trend of temporal hollowing, some of which may be attributed to soft tissue atrophy as well as bone reshaping over time (Fearon et al., 2009; Steinbacher et al., 2011; Seruya et al., 2014; Wes et al., 2014; Patel et al.,



2016). We may also not be fully capturing the deformity as we analyzed the contours in a single axial plane 20 mm above the glabella. With these limitations in mind, we hope to continue to investigate temporal trends and whether factors such as severity of the original deformity dictate degrees of recurrence.

Based on our findings, we believe these techniques have the potential to serve as a standardized measure of postoperative outcomes that can be used across practice settings. Future studies will focus on expanding our analysis to take full advantage of the 3-D data with a grid analysis utilizing X, Y, and Z plane coordinates and to compare outcomes of different surgical techniques.

### Authors' Note

This article was poster presented at Warren Alpert Medical School 6th Summer Showcase, on December 4, 2013, Providence, Rhode Island; presented at New England Society of Plastic and Reconstructive Surgery—55th Annual Meeting, on June 6-8, 2014, Sebasco Harbor, Maine; and presented at Plastic Surgery Research Council—60th Annual Meeting, on May 14-16, 2015, Seattle, Washington. Olivia Linden is now affiliated to Department of Radiology, University of California, San Francisco.

### Declaration of Conflicting Interests

The author(s) declared no potential conflicts of interest with respect to the research, authorship, and/or publication of this article.

### Funding

The author(s) received no financial support for the research, authorship, and/or publication of this article.

### References

- Chan FC, Kawamoto HK, Federico C, Bradley JP. Soft-tissue volumetric changes following monobloc distraction procedure. *J Craniofac Surg*. 2013;24(2):416-420.
- Cohen MM, MacLean RB. *Craniosynostosis: Diagnosis, Evaluation, and Management*. 2nd ed. New York, NY: Oxford University Press; 2000.
- Fearon JA, Ruotolo RA, Kolar JC. Single sutural craniosynostoses: surgical outcomes and long-term growth. *Plast Reconstr Surg*. 2009;123(2):635-642.
- Freudlsperger C, Steinmacher S, Bächli H, Somlo E, Hoffmann J, Engel M. Metopic synostosis: measuring intracranial volume change following fronto-orbital advancement using three-dimensional photogrammetry. *J Cranio-Maxillofacial Surg*. 2015;43(5):593-598.
- Hankinson TC, Fontana EJ, Anderson RCE, Feldstein NA. Surgical treatment of single-suture craniosynostosis: an argument for quantitative methods to evaluate cosmetic outcomes. *J Neurosurg Pediatr*. 2010;6(2):193-197.
- Honrado CP, Larrabee WF. Update in three-dimensional imaging in facial plastic surgery. *Curr Opin Otolaryngol Head Neck Surg*. 2004;12(4):327-331. <http://www.ncbi.nlm.nih.gov/pubmed/15252256>. Accessed February 8, 2016.
- Kau CH, Richmond S, Incrapera A, English J, Xia JJ. Three-dimensional surface acquisition systems for the study of facial morphology and their application to maxillofacial surgery. *Int J Med Robot Comput Assist Surg*. 2007;3(2):97-110.
- Lübbers H-T, Medinger L, Kruse A, Grätz KW, Matthews F. Precision and accuracy of the 3dMD photogrammetric system in craniomaxillofacial application. *J Craniofac Surg*. 2010;21(3):763-767.
- Marcus JR, Stokes TH, Mukundan S, Forrest CR. Quantitative and qualitative assessment of morphology in sagittal synostosis: mid-sagittal vector analysis. *J Craniofac Surg*. 2006;17(4):680-686.
- Othman SA, Ahmad R, Merican AF, Jamaludin M. Reproducibility of facial soft tissue landmarks on facial images captured on a 3D camera. *Aust Orthod J*. 2013;29(1):59-65.
- Patel KB, Skolnick GB, Mulliken JB. Anthropometric outcomes following fronto-orbital advancement for metopic synostosis. *Plast Reconstr Surg*. 2016;137(5):1539-1547.
- Plooij JM, Swennen GRJ, Rangel FA, Maal TJJ, Schutyser FAC, Bronkhorst EM, Kuijpers-Jagtman AM, Berge SJ. Evaluation of reproducibility and reliability of 3D soft tissue analysis using 3D stereophotogrammetry. *Int J Oral Maxillofac Surg*. 2009;38(3):267-273.
- Seruya M, Shen SH, Wang LL, Penington AJ, Wray AC, Greensmith AL, Holmes AD, Chong DK. Three patterns of fronto-orbital remodeling for metopic synostosis. *Plast Reconstr Surg*. 2014;134(5):787e-795e.
- Steinbacher DM, Wink J, Bartlett SP. Temporal hollowing following surgical correction of unicoronal synostosis. *Plast Reconstr Surg*. 2011;128(1):231-240.
- Weathers WM, Khechoyan D, Wolfswinkel EM, Mohan K, Nagy A, Bollo RJ, Buchanan EP, Hollier LH Jr. A novel quantitative method for evaluating surgical outcomes in craniosynostosis: pilot analysis for metopic synostosis. *Cranio-Maxillofacial Trauma Reconstr*. 2014;7(1):1-8.
- Wes AM, Paliga JT, Goldstein JA, Whitaker LA, Bartlett SP, Taylor JA. An evaluation of complications, revisions, and long-term aesthetic outcomes in nonsyndromic metopic craniosynostosis. *Plast Reconstr Surg*. 2014;133(6):1453-1464.
- Wilbrand JF, Szczukowski A, Blecher JC, Pons-Kuehnemann J, Christophis P, Howaldt HP, Schaaf H. Objectification of cranial vault correction for craniosynostosis by three-dimensional photography. *J Cranio-Maxillofacial Surg*. 2012;40(8):726-730.
- Wong JY, Oh AK, Ohta E, Hunt AT, Rogers GF, Mulliken JB, Deutsch CK. Validity and reliability of craniofacial anthropometric measurement of 3D digital photogrammetric images. *Cleft Palate-Craniofacial J*. 2008;45(3):232-239.
- Wong KWY, Forrest CR, Goodacre TEE, Klassen AF. Measuring outcomes in craniofacial and pediatric plastic surgery. *Clin Plast Surg*. 2013;40(2):305-312.